

ASB pre-doctoral young investigator award 2001

## In vivo motion of the rectus femoris muscle after tendon transfer surgery

Deanna S. Asakawa<sup>a,c</sup>, Silvia S. Blemker<sup>a</sup>, Garry E. Gold<sup>b,c</sup>, Scott L. Delp<sup>a,\*</sup>

<sup>a</sup>Department of Mechanical Engineering, Stanford University, Stanford, CA 94305-3030, USA

<sup>b</sup>Department of Radiology, Stanford University, Stanford, CA 94305-3030, USA

<sup>c</sup>Diagnostic Radiology Center, VA Palo Alto Health Care System, Palo Alto, CA, USA

Accepted 8 March 2002

### Abstract

Rectus femoris transfer surgery is performed to convert the rectus femoris muscle from a knee extensor to a knee flexor. In this surgery, the distal tendon of the rectus femoris is detached from the patella and reattached to one of the knee flexor tendons. The outcomes of this procedure are variable, and it is not known if the surgery successfully converts the muscle to a knee flexor. We measured the motion of muscle tissue within the rectus femoris and vastus intermedius during knee extension in 10 unimpaired control subjects (10 limbs) and 6 subjects (10 limbs) after rectus femoris transfer using cine phase-contrast magnetic resonance imaging. Displacements of the vastus intermedius during knee extension were similar between control and tendon transfer subjects. In the control subjects, the rectus femoris muscle consistently moved in the direction of the knee extensors and displaced *more* than the vastus intermedius. The rectus femoris also moved in the direction of the knee extensors in the tendon transfer subjects; however, the transferred rectus femoris displaced *less* than the vastus intermedius. These results suggest that the rectus femoris is not converted to a knee flexor after its distal tendon is transferred to the posterior side of the knee, but its capacity for knee extension is diminished by the surgery. © 2002 Elsevier Science Ltd. All rights reserved.

**Keywords:** Muscle; Magnetic resonance imaging; Rectus femoris; Tendon transfer; Cerebral palsy

### 1. Introduction

Tendon transfer surgeries are performed to alter the action of a muscle and improve movement in persons with neurological impairments. For example, rectus femoris tendon transfer surgery is performed to improve knee motion in persons with cerebral palsy who walk with a stiff-knee gait (Chambers et al., 1998; Gage et al., 1987; Ounpuu et al., 1993a, b; Perry, 1987; Sutherland et al., 1990). Stiff-knee gait, characterized by inadequate knee flexion during the swing phase, is often associated with over-activity of the rectus femoris, a knee extensor muscle (Perry, 1987). In rectus femoris transfer surgery, the distal tendon of the rectus femoris is detached from the patella and reattached to one of the knee flexor muscles, such as the sartorius or the semitendinosus (Gage et al., 1987; Miller et al., 1997; Patrick, 1996).

This surgery is performed in an attempt to convert the muscle from a knee extensor to a knee flexor and improve knee flexion; however, improvements in knee flexion are not observed in all patients.

It is unclear if rectus femoris transfer surgery successfully converts the muscle to a knee flexor. Anatomical studies have demonstrated that the rectus femoris muscle has a knee flexion moment arm after surgical transfer (Delp et al., 1994). However, stimulation of the rectus femoris muscle after surgery generated a knee extension moment (Riewald and Delp, 1997). How can a muscle that inserts posterior to the knee generate a knee extension moment? It is possible that adhesive scar tissue may form between the rectus femoris and the surrounding muscles and restrict the motion of the rectus femoris, compromising the muscle's ability to transmit force through its distal tendon. Consequently, the muscle could continue to act as a knee extensor and the outcome of the surgery could be degraded. To improve outcomes, we need to understand the in vivo action of the muscle after surgery.

\*Corresponding author. Tel.: +1-650-723-1230; fax: +1-650-725-1587.

E-mail address: delp@stanford.edu (S.L. Delp).

The purpose of this study was to gain insight into the action of the rectus femoris muscle after tendon transfer surgery using dynamic magnetic resonance imaging. Cine phase-contrast magnetic resonance imaging (cine-PC MRI) accurately captures the musculoskeletal anatomy and the velocity of bones and muscle tissue during joint motion (Drace and Pelc, 1994a, c; Pappas, 2001; Sheehan et al., 2000). Based on the direction of the muscle tissue velocity, one can identify a muscle's action (e.g., during knee extension, muscles that move superiorly are knee extensors and muscles that move inferiorly are knee flexors). Additionally, based on relative velocities of the muscles, one can identify the relative magnitude of each muscle's moment arm (e.g., during knee extension, a knee extensor with a larger moment arm will have greater superior velocity than a knee extensor with a smaller moment arm). We hypothesized that during knee extension the rectus femoris would move in the same direction as the vastus intermedius, a knee extensor, in unimpaired subjects and in the direction of the hamstrings muscles, knee flexors, in subjects who have undergone rectus femoris transfer surgery. We tested this hypothesis using cine-PC MRI to quantify the velocity and displacement of the rectus femoris relative to the vastus intermedius and hamstrings during knee extension. This study is the first to use dynamic MRI to evaluate muscle motion after tendon transfer surgery.

## 2. Methods

### 2.1. Subjects

Magnetic resonance images of the lower limb were acquired from the dominant side of 10 unimpaired control subjects (age: 23–38 yr, height: 162–175 cm, 5 female, 5 male) and from 10 limbs of 6 subjects with cerebral palsy after rectus femoris tendon transfer surgery (Table 1). All of these subjects had undergone concomitant soft tissue surgeries, including hamstring

lengthenings, tendo-achilles lengthenings, adductor myotomies, and psoas tenotomies. No subject had undergone bone surgery. The Institutional Review Board at Stanford University approved the imaging protocols. Each subject was screened for magnetic resonance imaging risk factors and provided informed consent in accordance with institutional policy.

### 2.2. MR image acquisition

The goal of the MR imaging was to characterize the *in vivo* action of rectus femoris, vastus intermedius, and hamstring muscles by measuring the muscle tissue velocities during knee extension. To do this we used cine-PC MRI. Cine-PC MRI is a dynamic imaging technique that requires numerous cycles of repeated motion to acquire multiple time frames of composite images representing one motion cycle (Drace and Pelc, 1994b; Pelc et al., 1991; Sheehan et al., 1998). The cine-PC pulse sequence encodes the three-dimensional tissue velocities in the phase of the MR signal; thus, for each of 24 frames in a cine-PC MRI movie, we obtained one anatomy image and three orthogonal direction velocity images. The tissue velocity is depicted in the grayscale value of each pixel in the velocity images. We encoded velocities in the range of  $-20$  to  $+20$  cm/s.

Each subject was positioned supine on the table of a 1.5 T GE scanner (GE Medical Systems, Milwaukee, WI). We carefully positioned the subjects to minimize thigh movement. The limb was placed between dual general-purpose radiofrequency coils, which were held on vertical supports (Fig. 1). The subject's limb was supported in  $30$ – $40^\circ$  of hip flexion and  $55$ – $65^\circ$  of knee flexion. This allowed a knee range of motion within the scanner of approximately  $40^\circ$ . An optical transducer placed near the foot was used to trigger the MR scanner at the beginning of each motion cycle. A device was attached to the subject's ankle to allow the investigator to move the subject's leg passively through a range of knee flexion and extension during dynamic image acquisition. The inability of the rectus femoris transfer

Table 1  
Characteristics of the rectus femoris transfer subjects

Subject	Gender	Age (yr)	Height (cm)	Transfer site	Time since rectus femoris transfer (yr)
1 <sup>a</sup>	F	13.5	158	Iliotibial band	0.7
2 <sup>b</sup>	M	12.9	148	Sartorius	0.8
3 <sup>c</sup>	F	15.6	155	Sartorius	1.6
4 <sup>b</sup>	M	8.8	125	Semitendinosus	3.0
5 <sup>b</sup>	M	14.8	158	Semitendinosus	3.2
6 <sup>b</sup>	F	16.6	155	Sartorius	9.0

<sup>a</sup>Surgery performed at the Oakland Children's Hospital, Oakland, CA.

<sup>b</sup>Surgery performed at the Shriners' Hospital for Children, Sacramento, CA.

<sup>c</sup>Surgery performed at University of California at Davis Medical Center, Davis, CA.

subjects to repeatably flex and extend their knee through multiple motion cycles necessitated use of this device. Both control and rectus femoris transfer subjects were imaged as their knee was moved through 100 repeated cycles of knee extension–flexion at a rate of 35 cycles/min to the beat of a metronome. We assumed that passive knee motion preserves the action of the muscles. To test this assumption, we acquired an additional set of cine-PC MR images from the control subjects as they actively moved their knee against the load of gravity and compared muscle motion during this low-level active knee extension to muscle motion during passive knee extension.

We acquired static and cine-PC MR images from all subjects. We used the static MR images to prescribe the

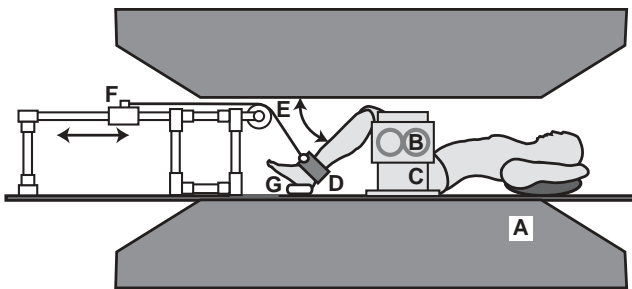


Fig. 1. Experimental setup. The subject was positioned supine in the MRI scanner (A). Dual general-purpose radiofrequency coils (B) were held on vertical supports (C) on either side of the limb being imaged. The subject's ankle was placed in a cuff (D) attached to ropes that pass over a pulley (E) and attach to the handle of a slider mechanism (F). The subject's knee was moved through extension and flexion during cine-PC MR image acquisition by moving the slider handle on the device. An optical transducer (G) placed near the foot triggered the beginning of each motion cycle.

imaging plane locations for two series of the cine-PC MR images. In the first series, we prescribed an oblique sagittal imaging plane that best aligned with the long axis of the rectus femoris to minimize out-of-plane motion. It was often difficult to prescribe this oblique sagittal plane through a substantial part of the transferred rectus femoris muscle due to the complex path of this muscle after surgery. Therefore, in the second imaging series we prescribed an axial imaging plane at the mid-thigh that was perpendicular to the long axis of the femur to ensure we had captured the velocity of the transferred rectus femoris muscle. All cine-PC MR images were acquired with a 17 ms repetition time (TR), 30° flip angle, 256 × 128 matrix, and 1 cm slice thickness. A 36 × 27 cm field of view was used for all sagittal plane cine-PC images. For the axial plane cine-PC images, we prescribed either a 36 × 27 or 28 × 21 cm field of view depending on the subject's thigh circumference.

### 2.3. Calculation of muscle motions

We characterized the superior–inferior motion of the rectus femoris, vastus intermedius, and hamstrings during knee extension with cine-PC MRI in both the sagittal and axial imaging planes. Sagittal plane cine-PC MR images were acquired from all control subjects and 4 rectus femoris transfer subjects. The displacements of 1 cm square regions in the mid-thigh portion of the rectus femoris and the vastus intermedius muscles (Fig. 2) were calculated by integrating the three-dimensional velocity image data using a closed-form Fourier integration method (Zhu et al., 1996). A 0.5 cm square region was used for the rectus femoris transfer subjects

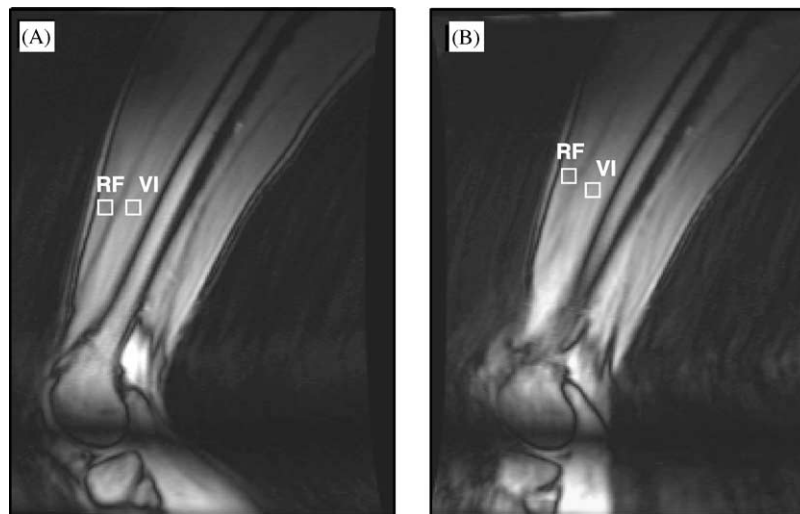


Fig. 2. Sagittal plane cine-PC MR images of the thigh. Positions of 1 cm square tissue regions (white boxes) depict displacement of rectus femoris (RF) relative to vastus intermedius (VI) during active extension from approximately 65° of knee flexion (A) to near full extension (B) for one of the control subjects.

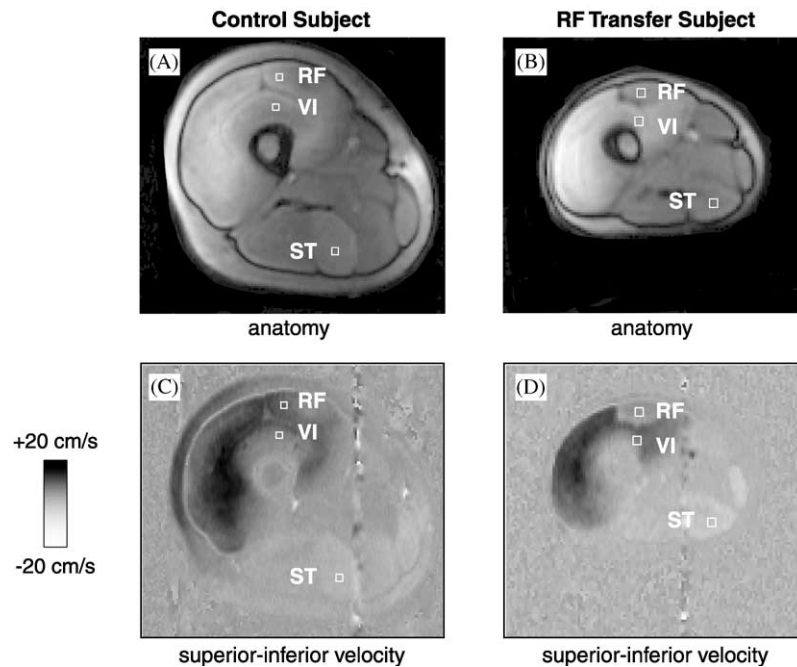


Fig. 3. Axial plane anatomy images (A—control, B—rectus femoris transfer) at one time frame during knee extension show the locations of square regions within the rectus femoris (RF), vastus intermedius (VI), and semitendinosus (ST). Superior–inferior velocity images (C—control, D—rectus femoris transfer) are shown at the same time frame; velocity is depicted in the grayscale of the images (see legend) with dark pixels indicating superior velocity and light pixels indicating inferior velocity during knee extension. Superior–inferior velocities are perpendicular to the axial plane. These axial plane images depict lower velocity of muscle tissue within the transferred rectus femoris compared to the vastus intermedius muscles (D).

because these subjects had smaller muscles. For each subject, we tracked displacements of a square region in the hamstring muscle that was best aligned with the oblique sagittal imaging plane (semitendinosus, semimembranosus, or biceps femoris long head) to identify the direction of the knee flexor muscle motion. All displacements were normalized by the peak vastus intermedius displacement during knee extension. This gave a measure of the relative displacement of rectus femoris with respect to the displacement of the vastus intermedius muscle tissue. Examining the displacements relative to vastus intermedius reduced the effects of inter-subject variability and established the vastus intermedius as a base of comparison between control subjects and rectus femoris transfer subjects. Paired *t*-tests were used to compare displacements between the active and passive motion tasks for both the rectus femoris and vastus intermedius muscles in the control subjects. Statistical powers for the *t*-tests were 67% and 80% for the rectus femoris and vastus intermedius, respectively.

Superior–inferior velocities of the rectus femoris, vastus intermedius, and hamstrings were quantified from the axial plane cine-PC MR images of 5 control subjects and all of the rectus femoris transfer subjects. In the axial plane images, the superior–inferior direction is perpendicular to the imaging plane. On the axial plane velocity images we prescribed 0.25 cm square regions at

the middle of the cross section of the rectus femoris, vastus intermedius, and semitendinosus (Fig. 3). The average superior–inferior velocity of tissue within these regions was computed for each time frame using the MATLAB image processing toolbox (The Mathworks, Inc., Natick, MA). For each time frame, the average and standard deviation of the velocity of the pixels within each square region was computed. We compared the average velocity of the rectus femoris muscle to the average velocity of the vastus intermedius and hamstrings to gauge the magnitude and direction of rectus femoris motion.

### 3. Results

The rectus femoris and vastus intermedius displaced in the same direction (superiorly) when control subjects actively extended the knee against gravity (Fig. 4). There was no statistical difference in the average displacements of the rectus femoris between the active and passive knee extension tasks (Fig. 5); the same was true for the vastus intermedius muscle. Displacements of the regions of interest were on average 31% greater in the rectus femoris than in the vastus intermedius during active knee extension in the control subjects. The average displacement of tissue within the rectus femoris was significantly greater ( $p < 0.005$ ) than the average

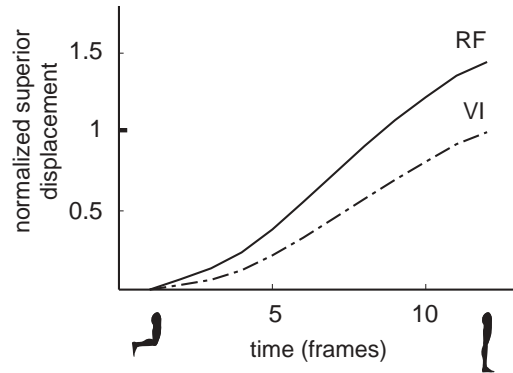


Fig. 4. Rectus femoris and vastus intermedius muscle tissue displacements during active knee extension for one control subject. Displacements of the regions of interest within the rectus femoris (RF) and vastus intermedius (VI) are plotted for the time frames of cine-PC MR images acquired during active knee extension. The subject extended the knee from approximately 65° of knee flexion and to near full extension. Displacements were normalized by peak vastus intermedius displacement. Positive displacement values indicate superior motion of these knee extensor muscles during knee extension.

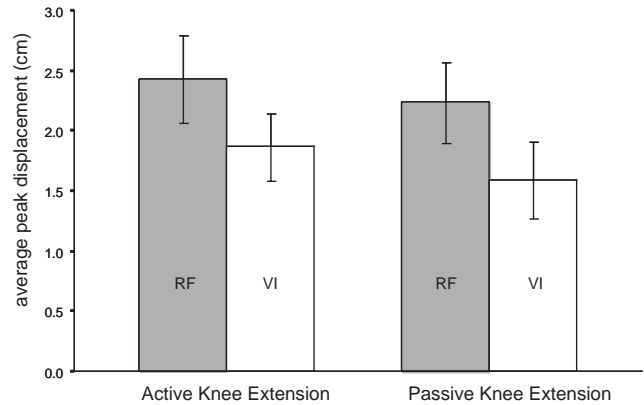


Fig. 5. Average peak muscle tissue displacements during active and passive knee extension. Peak displacements averaged for the 10 control subjects illustrate that rectus femoris (RF—shaded bar) displaces significantly more than vastus intermedius (VI—white bar) during the low-level active task when the control subjects extended the knee against the load of gravity and in the passive task when the limb was moved passively into knee extension by the investigator. There was no difference in average peak RF displacement or average peak VI displacement between active and passive knee extension.

displacement of tissue within the vastus intermedius for both active and passive knee extension in the control subjects.

In the rectus femoris transfer subjects (Fig. 6), the rectus femoris also displaced in the direction of the vastus intermedius (knee extensors), not the hamstrings (knee flexors). However, in contrast to the control subjects, the rectus femoris displaced less than the vastus intermedius by 2% (subject 5) to 77% (subject 2) after tendon transfer. The average peak vastus intermedius displacement for the rectus femoris transfer subjects was 1.5 cm compared to an average peak displacement of 1.6 cm measured during passive motion in the control subjects.

Velocity measurements from the axial plane cine-PC images were consistent with the displacements measured from the sagittal plane images. The rectus femoris and vastus intermedius moved superiorly and the hamstrings moved inferiorly in the control subjects and the rectus femoris transfer subjects (Fig. 7). All of the rectus femoris transfer subjects had rectus femoris velocities in the direction of the knee extensors (Table 2); however, the peak rectus femoris velocities were less than the peak vastus intermedius velocities. These results indicate that rectus femoris transfer surgery does not convert the rectus femoris to a knee flexor, but diminishes the muscle's capacity for knee extension.

#### 4. Discussion

Rectus femoris transfer is performed to improve knee flexion during walking in persons with a stiff-knee gait. It is thought that transfer of the rectus femoris may

improve knee flexion by converting this muscle from a knee extensor to a knee flexor. However, the rectus femoris muscle did not move in the direction of the knee flexors in any of the 10 limbs that had undergone a rectus femoris transfer. This result is consistent with measurement of knee extension moments during stimulation of transferred rectus femoris muscles (Riewald and Delp, 1997). However, the extension capacity of the rectus femoris was decreased after surgery, as demonstrated by its diminished velocity and displacement during knee extension.

The result that the transferred rectus femoris does not act as a knee flexor is somewhat surprising considering that its path is surgically altered to insert into a knee flexor muscle or tendon. One possible explanation is that scar tissue may form after surgery, constraining the motion of the muscle and diminishing the force transmitted to its distal tendon. Several studies have suggested that scar tissue or adhesions that arise from tendon transfer surgeries in the upper limb may restrict tendon motion and degrade the surgical outcome (Freehafer et al., 1988; Friden et al., 2001; Strickland, 2000). Other studies have suggested that muscles can transmit force through connective tissue to neighboring muscles (Huijing, 1999; Maas et al., 2001). Although tendon transfers are frequently performed assuming that force will be transmitted effectively through the distal tendon, our data and other studies suggest that this is not always true.

There are several potential limitations to this study. First, our control subjects were not age-matched or size-matched with the rectus femoris transfer subjects. However, we normalized muscle tissue displacements

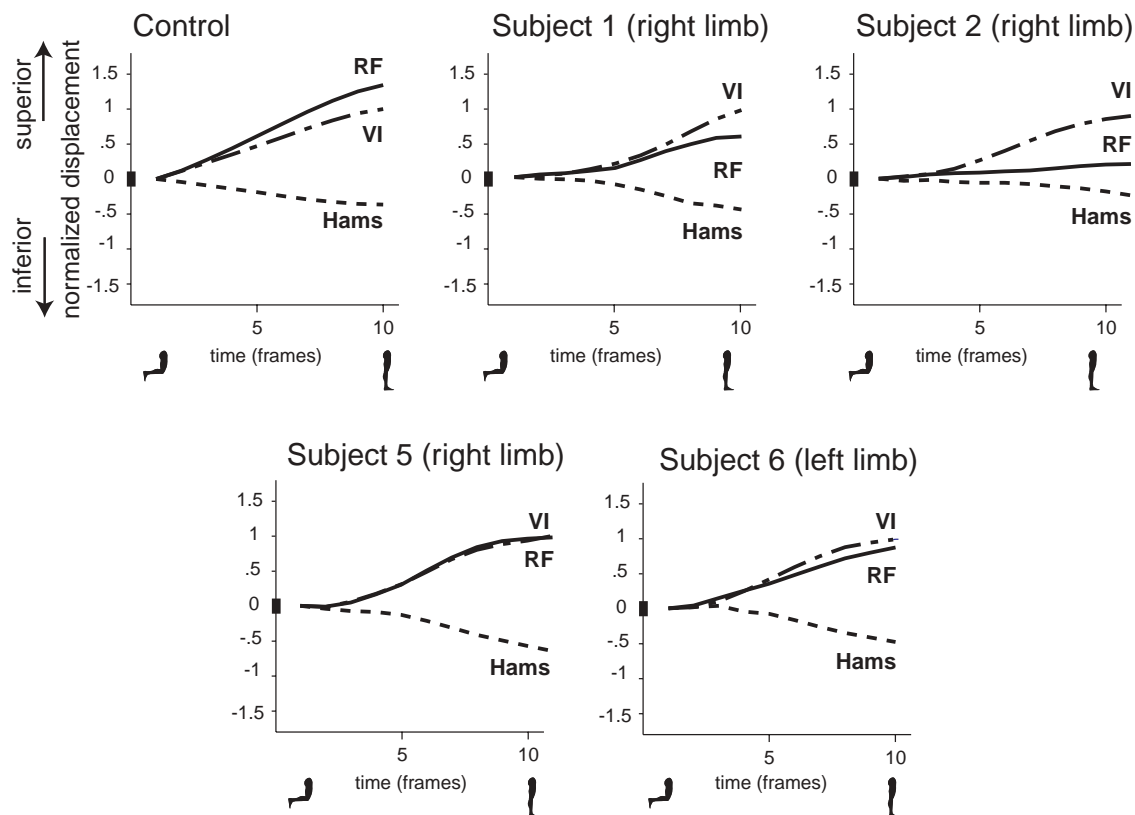


Fig. 6. Displacements of regions of interest within the vastus intermedius (VI), rectus femoris (RF), and hamstrings (Hams) during passive knee extension. Displacements, normalized by peak VI displacement, are plotted for a control subject and 4 rectus femoris transfer subjects. Positive displacement indicates superior motion of a muscle with knee extension, and negative displacements indicate inferior motion of a muscle with knee extension. After surgical transfer to a knee flexor, the rectus femoris displaced in the direction of the knee extensors (VI), but in contrast to the control subject, the rectus femoris displaced less than the vastus intermedius muscle.

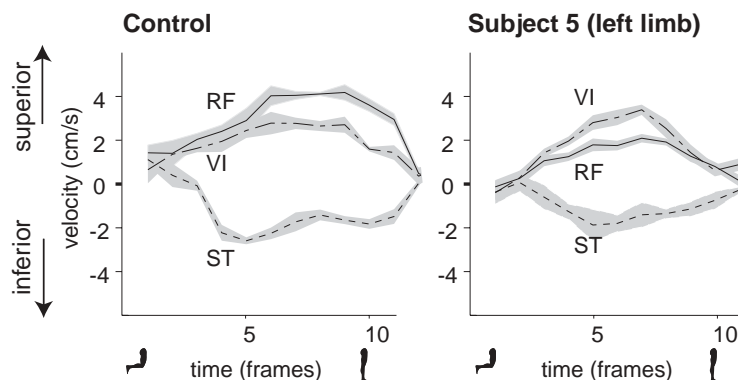


Fig. 7. Velocity measurements from axial plane cine-PC images. The average (lines) and standard deviation (shaded region) of tissue velocity within the square regions in the rectus femoris (RF), vastus intermedius (VI), and semitendinosus (ST) are plotted for all time frames of knee extension for one control subject and rectus femoris transfer subject 5 (left limb). The velocities indicate that the RF and VI muscles moved superiorly while the ST, a knee flexor, moved inferiorly for both the control and the rectus femoris transfer subject.

by each subject's peak vastus intermedius displacement to reduce the effects of differences in subject sizes. Second, only six rectus femoris transfer subjects (10 limbs) were imaged in this study. While the rectus femoris moved in the direction of the knee extensors in all of these subjects, it is possible that the rectus femoris

is converted to a knee flexor in other subjects. Variations in surgical technique, transfer site, and rehabilitation regimen may influence the function of the muscle after surgery (Chambers et al., 1998; Gage et al., 1987; Jamali et al., 2000; Miller et al., 1997; Patrick, 1996; Strickland, 2000). For this reason, the results presented in this study

Table 2  
Muscle tissue velocities after rectus femoris transfer

Subject	Side	RF velocity (cm/s) <sup>a</sup>	VI velocity (cm/s) <sup>a</sup>	Relative velocity <sup>b</sup>
1 <sup>c</sup>	Right	1.4	1.6	0.9
2	Left	1.5	2.5	0.6
	Right	1.1	1.6	0.7
3	Left	2.0	3.3	0.6
4	Left	0.1	3.0	0.0
	Right	1.1	2.7	0.4
5	Left	1.9	2.5	0.8
	Right	2.9	4.4	0.7
6	Left	1.6	3.0	0.5
	Right	2.3	2.5	0.9
Control <sup>d</sup>	Dominant	3.8±0.2	2.1±0.8	1.9±0.3

<sup>a</sup>Maximum velocity during knee extension. Positive values indicate superior motion.

<sup>b</sup>Relative velocity is computed as (RF velocity)/(VI velocity).

<sup>c</sup>Velocities computed from sagittal plane cine-PC images.

<sup>d</sup>Average and standard deviation velocity values for 5 unimpaired adults during passive knee extension.

may not be representative of all rectus femoris transfer outcomes.

Our conclusion that the rectus femoris does not act as a knee flexor after surgery is dependent on accurate measurement of the direction of the muscle tissue velocities. Cine-PC MRI has been demonstrated to have sub-millimeter accuracy for tracking bone and muscle motion (Drace and Pelc, 1994b; Sheehan et al., 1998). The magnitude of the velocities may vary among subjects due to differences in size, range of motion, the location of the regions of tracked tissue within the muscle, and other factors. However, assuming that the hip joint is fixed and the tendons are non-compliant, the direction of the muscle velocity during knee extension depends only on the muscle's action (e.g., as a knee flexor or extensor). The vastus intermedius and hamstring muscles had velocities in directions that are consistent with their mechanical action in control subjects and rectus femoris transfer subjects. Additionally, the sartorius had velocity, as measured from axial plane cine-PC images, in the opposite direction of the vastus intermedius, despite the proximity of these two muscles in the proximal thigh. The accuracy of the technique and the measurement of velocities in the expected directions for the non-surgically altered muscles gives confidence that cine-PC MRI accurately captures the direction of muscle tissue motion in vivo.

The velocity of the muscles reported during passive knee motion may not represent the velocities of active muscles during walking. We passively moved the limbs of the subjects with cerebral palsy so that the number of knee motion cycles required for this dynamic imaging

technique could be completed in a repeatable manner and the quality of the MRI data was maintained. We believe that passive knee motion preserves the direction of motion of the muscles because the muscle tissue displacements were similar in the passive and low-level active knee extension tasks in the control subjects (Fig. 4). However, we expect that the magnitude of the tissue velocities reported here might be different from the tissue velocities during activities that produce large muscle forces.

Previous studies document improved knee motion in subjects after rectus femoris tendon transfer (Chambers et al., 1998; Gage et al., 1987; Miller et al., 1997; Ounpuu et al., 1993a; Sutherland et al., 1990). Some of the rectus femoris transfer subjects included in our study also demonstrated improvements in knee flexion post-operatively. Our results indicate that the mechanism for improved knee flexion in some subjects following rectus femoris transfer is unlikely to be a knee flexion moment generated by the rectus femoris. Rectus femoris transfer may instead improve knee flexion by lessening the muscle's ability to extend the knee while preserving its capacity to generate a hip flexion moment, which promotes knee flexion (Kerrigan et al., 1998; Piazza and Delp, 1996). Improvements in some patients' gaits may result from one or more of the concomitant surgical procedures or the combination of rectus femoris transfer and other surgeries. Therefore, as demonstrated by some subjects, the surgical goals of increasing knee range of motion, maintaining or increasing swing phase knee flexion, and improving the timing of peak knee flexion may be achieved even if the

transferred rectus femoris does not generate a knee flexion moment.

Computer simulations (Delp et al., 1994; Dul et al., 1985; Herrmann and Delp, 1999; Murray et al., 2001), intra-operative measurements (Lieber and Friden, 1997), and animal studies (Friden et al., 2000; Zhao et al., 2001) have provided important insights into muscle function after tendon transfer surgery. Dynamic MRI complements these techniques by providing a means to visualize and measure muscle motion in vivo. These measurements are needed to establish a scientific basis for understanding muscle function after surgery.

### Acknowledgements

We are thankful to Anita Bagley, George Rab, Scott Hoffinger, Scott Riewald, George Pappas, John Drace, and Doug Schwandt. We are grateful to the staff of the Motion Analysis Laboratory at Shriners Hospitals for Children, Northern California, for recruiting subjects. Funding for this work was provided by the National Institutes of Health Grants HD38962 and T32 GM63495 and graduate fellowships from the Whitaker Foundation, the National Science Foundation, and the American Association of University Women.

### References

- Chambers, H., Lauer, A., Kaufman, K., Cardelia, J.M., Sutherland, D., 1998. Prediction of outcome after rectus femoris surgery in cerebral palsy: the role of cocontraction of the rectus femoris and vastus lateralis. *Journal of Pediatric Orthopedics* 18, 703–711.
- Delp, S.L., Ringwelski, D.A., Carroll, N.C., 1994. Transfer of the rectus femoris: effects of transfer site on moment arms about the knee and hip. *Journal of Biomechanics* 27, 1201–1211.
- Drace, J.E., Pelc, N.J., 1994a. Elastic deformation in tendons and myotendinous tissue: measurement by phase-contrast MR imaging. *Radiology* 191, 835–839.
- Drace, J.E., Pelc, N.J., 1994b. Measurement of skeletal muscle motion in vivo with phase-contrast MR imaging. *Journal of Magnetic Resonance Imaging* 4, 157–163.
- Drace, J.E., Pelc, N.J., 1994c. Skeletal muscle contraction: analysis with use of velocity distributions from phase-contrast MR imaging. *Radiology* 193, 423–429.
- Dul, J., Shiavi, R., Green, N.E., 1985. Simulation of tendon transfer surgery. *Engineering in Medicine* 14, 31–38.
- Freehafer, A.A., Peckham, P.H., Keith, M.W., Mendelson, L.S., 1988. The brachioradialis: anatomy, properties, and value for tendon transfer in the tetraplegic. *Journal of Hand Surgery* 13, 99–104.
- Friden, J., Albrecht, D., Lieber, R.L., 2001. Biomechanical analysis of the brachioradialis as a donor in tendon transfer. *Clinical Orthopaedics and Related Research* 383, 152–161.
- Friden, J., Ponten, E., Lieber, R.L., 2000. Effect of muscle tension during tendon transfer on sarcomerogenesis in a rabbit model. *Journal of Hand Surgery* 25, 138–143.
- Gage, J.R., Perry, J., Hicks, R.R., Koop, S., Werntz, J.R., 1987. Rectus femoris transfer to improve knee function of children with cerebral palsy. *Developmental Medicine and Child Neurology* 29, 159–166.
- Herrmann, A.M., Delp, S.L., 1999. Moment arm and force-generating capacity of the extensor carpi ulnaris after transfer to the extensor carpi radialis brevis. *Journal of Hand Surgery* 24, 1083–1090.
- Huijing, P.A., 1999. Muscle as a collagen fiber reinforced composite: a review of force transmission in muscle and whole limb. *Journal of Biomechanics* 32, 329–345.
- Jamali, A.A., Afshar, P., Abrahms, R.A., Lieber, R.L., 2000. Skeletal muscle response to tenotomy. *Muscle and Nerve* 23, 851–862.
- Kerrigan, D.C., Roth, R.S., Riley, P.O., 1998. The modelling of adult spastic paretic stiff-legged gait swing period based on actual kinematic data. *Gait and Posture* 7, 117–124.
- Lieber, R.L., Friden, J., 1997. Intraoperative measurement and biomechanical modeling of the flexor carpi ulnaris-to-extensor carpi radialis longus tendon transfer. *Transactions of the ASME* 119, 386–391.
- Maas, H., Baan, G.C., Huijing, P.A., 2001. Intermuscular interaction via myofascial force transmission: effects of tibialis anterior and extensor hallucis longus length on force transmission from rat extensor digitorum longus muscle. *Journal of Biomechanics* 34, 927–940.
- Miller, F., Cardoso Dias, R., Lipton, G.E., Albarracin, J.P., Dabney, K.W., Castagno, P., 1997. The effect of rectus femoris transfers. *Journal of Pediatric Orthopaedics* 17, 603–607.
- Murray, W.M., Bryden, A.M., Kilgore, K.L., Keith, M.W., 2001. Wrist range of motion depends on elbow position after Br-ECRB tendon transfer. *Proceedings of the XVIIIth Congress of the International Society of Biomechanics, Zurich, Switzerland*, pp. 367–368.
- Ounpuu, S., Muik, E., Davis, R.B., Gage, J.R., DeLuca, P.A., 1993a. Rectus femoris surgery in children with cerebral palsy. Part I: the effect of rectus femoris transfer location on knee motion. *Journal of Pediatric Orthopaedics* 13, 325–330.
- Ounpuu, S., Muik, E., Davis, R.B., Gage, J.R., DeLuca, P.A., 1993b. Rectus femoris surgery in children with cerebral palsy. Part II: a comparison between the effect of transfer and release of the distal rectus femoris on knee motion. *Journal of Pediatric Orthopaedics* 13, 331–335.
- Pappas, G., 2001. Characterization of biceps brachii architecture and contraction mechanics using medical imaging techniques. Ph.D. Dissertation, Stanford University, Stanford, CA.
- Patrick, J.H., 1996. Techniques of psoas tenotomy and rectus femoris transfer: new operations for cerebral palsy diplegia—a description. *Journal of Pediatric Orthopaedics Part B* 5, 242–246.
- Pelc, N.J., Herfkens, R.J., Shimakawa, A., Enzmann, D.R., 1991. Phase contrast cine magnetic resonance imaging. *Magnetic Resonance Quarterly* 7, 229–254.
- Perry, J., 1987. Distal rectus femoris transfer. *Developmental Medicine and Child Neurology* 29, 153–158.
- Piazza, S.J., Delp, S.L., 1996. The influence of muscles on knee flexion during the swing phase of gait. *Journal of Biomechanics* 29, 723–733.
- Riewald, S.A., Delp, S.L., 1997. The action of the rectus femoris muscle following distal tendon transfer: does it generate a knee flexion moment? *Developmental Medicine and Child Neurology* 39, 99–105.
- Sheehan, F.T., Pappas, G., Drace, J.E., 2000. In vivo measures of musculoskeletal dynamics using cine phase contrast magnetic resonance imaging. In: *Skeletal muscle mechanics: from mechanisms to function*. Wiley, New York, pp. 343–363.
- Sheehan, F.T., Zajac, F.E., Drace, J.E., 1998. Using cine phase contrast magnetic resonance imaging to non-invasively study in vivo knee dynamics. *Journal of Biomechanics* 31, 21–26.
- Strickland, J.W., 2000. Development of flexor tendon surgery: twenty-five years of progress. *Journal of Hand Surgery* 25, 214–235.



- Sutherland, D.H., Santi, M., Abel, M.F., 1990. Treatment of stiff-knee gait in cerebral palsy: a comparison by gait analysis of distal rectus femoris transfer versus proximal rectus release. *Journal of Pediatric Orthopaedics* 10, 433–441.
- Zhao, C., Amadio, P.C., Momose, T., Couvreur, P., Zobitz, M.E., An, K.N., 2001. The effect of suture technique on adhesion formation after flexor tendon repair for partial lacerations in a canine model. *Journal of Trauma Injury, Infection, and Critical Care* 51, 917–921.
- Zhu, Y., Drangova, M., Pelc, N., 1996. Fourier tracking of myocardial motion using cine-PC data. *Magnetic Resonance Medicine* 35, 471–480.