

Biomechanical Analysis of the Chiari Pelvic Osteotomy

Preserving Hip Abductor Strength

SCOTT L. DELP, M.S.,* EUGENE E. BLECK, M.D.,** FELIX E. ZAJAC, PH.D.,*
AND GERARD BOLLINI, M.D.†

Although the Chiari osteotomy is usually effective in reducing pain, many patients are left with a long-term limp. The postoperative limp can at times be caused by hip abductors that have strength insufficient to counteract the torque from body weight during single-leg stance. To study how the surgical technique affects the hip abductor muscles, a biomechanical model was developed that computes the postsurgery pelvic geometry and the resulting hip abductor torque given three surgical parameters: angulation of the osteotomy, distance of medial displacement, and angle of internal rotation. The computer simulations of the Chiari osteotomy showed that some sets of surgical parameters conserve abductor torque while others greatly reduce it. Simulated surgeries with high angulation and large medial displacement reduce gluteus medius abductor torque by up to 65%. Therefore, this combination of surgical parameters may account for some instances of the postoperative limp. In the model, high angulation reduces the length of the gluteus medius and is the primary cause of reduced abductor strength. Simulated horizontal osteotomies (0° to 10°) were

found to best conserve both muscle length and abductor torque.

Treating subluxation of the hip, whether from congenital disorders, neuromuscular problems, or acquired disease, remains a challenge. Subluxation of the hip with secondary acetabular dysplasia is particularly difficult to manage when it becomes irreducible. To solve this problem, Chiari⁹ devised a medial displacement osteotomy of the pelvis. Initially, this procedure was recommended for all dysplastic hips. However, Chiari¹⁰ later stated that the medial displacement osteotomy is indicated only in children older than four years when Salter³⁴ and Pemberton³² procedures are contraindicated. Since its introduction, the Chiari osteotomy has become widely used to treat pain and instability of the hip in both children and adults.^{1,2,7,11,13,14,18-21,26,35,36}

In Chiari's procedure, the osteotomy starts from the lateral surface of the ilium at the level of the superior margin of the acetabulum and is directed medially and superiorly. Once the osteotomy is complete, the distal fragment is displaced medially to create a bony ceiling above the femoral head. Increased femoral head coverage improves hip stability. Medial displacement of the hip also reduces the body-weight moment arm (the perpendicular distance between the body-weight force vector and the hip joint center),

* Rehabilitation Research and Development Center, Veterans Administration Medical Center, Palo Alto, and Design Division, Mechanical Engineering Department, Stanford University, Stanford, California.

** Department of Surgery, Stanford University School of Medicine, Stanford, California.

† Hôpital d'enfants de la Timone, Marseille, France. Supported by a National Science Foundation Fellowship to Scott L. Delp and the Veterans Administration.

Reprint requests to Scott L. Delp, Rehabilitation Research and Development Center (153), Veterans Administration Medical Center, 3801 Miranda Ave., Palo Alto, CA 94304.

Received: October 25, 1988.

thereby decreasing the abductor torque required to counteract gravity.²⁸

Even though the Chiari osteotomy putatively reduces the gravitational torque that must be counteracted by the hip abductors, many patients develop a Trendelenburg gait after surgery.^{1,2,7,36} The Trendelenburg gait occurs when the hip abductors are unable to support the torque from body weight; consequently, the pelvis drops to the contralateral side during single-leg stance.^{22,33} Patients with weak abductors also frequently lurch over the involved hip to compensate for the weak muscles.^{23,33} The limp from abductor weakness must be differentiated from an antalgic gait that is similarly characterized by the patient leaning over the involved hip, in this case, however, to reduce the compressive joint load.²³ Although some have reported very few cases with the postoperative limp from abductor weakness,^{11,20,26} others have reported many.^{1,2,7,36} For example, Schulze and Kramer³⁶ reported that the Chiari osteotomy gave unsatisfactory results in 39 of 82 patients, primarily because of decreased abductor muscle strength. In a long-term follow-up study, Calvert *et al.*⁷ reported a positive Trendelenburg sign in 76% and a severe limp in 56% of 49 cases after surgery. Bailey and Hall¹ reported that 14 of 18 patients exhibited a Trendelenburg gait after a Chiari osteotomy was performed for acetabular dysplasia. It is puzzling that a procedure that presumably reduces the abductor torque required for pelvic stability often leads to a Trendelenburg gait.

The authors hypothesize that surgical modification of the musculoskeletal geometry may substantially reduce hip abductor strength and thus cause the limp. Because the distal fragment, with the hip joint and muscle insertions, moves relative to the proximal fragment, muscle lengths and moment arms are changed by the surgery. These mechanical changes may hinder the muscles' capacity to generate sufficient force and torque to support the pelvis during walking.

A biomechanical model of the Chiari oste-

otomy was developed to study how the surgical parameters affect hip abduction torque. The objective was to determine whether certain combinations of the surgical parameters significantly reduce abductor torque and to find a surgical technique that conserves abductor torque. This article first describes mathematical models of both the surgical procedure and the hip musculature. The results of two simulated surgeries are then shown to illustrate how the surgical parameters combine to affect abductor torque. Families of curves are presented to show the change in hip abductor torque for each surgical parameter. Finally, the clinical significance of these findings is discussed.

MATERIALS AND METHODS

To study how the Chiari osteotomy affects hip abductor torque, a computer model was developed to simulate the mechanical effects of the surgical procedure. The model is composed of two parts: (1) a surgical model that computes the locations of the muscle insertions and the hip joint center given values for the surgical parameters and (2) a musculoskeletal model that calculates the hip abductor torque given coordinates for the muscle attachments and the joint center, and values for the musculotendon parameters.

SURGICAL MODEL

A preliminary anatomic study was performed to ascertain how the changes in muscle attachment locations resulting from a Chiari osteotomy could be characterized. On each of three fresh anatomic specimens, the most anterior and posterior points of the gluteus medius origin were first marked with metal pins. The line connecting these two points was bisected, and marked with a pin, to locate a third point representing the medial origin. The distance from origin to insertion (musculotendon length) was then measured as the distance from each of the three metal pins to the insertion on the greater trochanter. A Chiari osteotomy was performed on each anatomic specimen with various angulation and displacement. The musculotendon lengths were again measured on each anatomic specimen. Measured changes in musculotendon length showed that it was nearly impossible to perform the osteotomy with no relative rotation of the two bone fragments. An internal rotation angle (representing the relative rotation) was therefore included in the surgical model

in addition to the angulation and the displacement.

As a result of the anatomic study and the authors' clinical experience, the Chiari osteotomy was characterized by three geometric parameters: angulation of the osteotomy, distance of medial displacement, and angle of internal rotation (Fig. 1). Angulation and displacement were defined by their projection in the frontal plane. Relative rotation of the two bone fragments was computed about a vertical axis passing through the sacroiliac joint. Even though the proximal fragment of the innominate bone may rotate about the sacroiliac joint, it was assumed to remain fixed while the distal fragment translates and rotates as a rigid body. The abductor muscle origins are therefore unchanged in the surgical model, but the joint center and muscle insertions do change and were computed with three-dimensional geometric transformations. The surgical model thus calculates the postsurgery hip joint center and muscle

insertions given values for the surgical parameters.

MUSCULOSKELETAL MODEL

The musculoskeletal model describes not only the geometric relationships of the muscles and bones (the musculoskeletal geometry) but also the musculotendon parameters, so that the maximum isometric hip abductor torque can be computed at any hip abduction angle. The musculoskeletal model thus consists of coordinates for muscle attachments and a model for each musculotendon compartment.

Presurgery coordinates for the three primary hip abductors were taken from data reported by Brand *et al.*⁴ Two of the hip abductors, the gluteus minimus and the tensor fasciae latae, were modeled as single lines from origin to insertion. The third, the gluteus medius, however, was decomposed into anterior, medial, and posterior musculotendon compartments (Fig. 2). From purely musculoskeletal geometric data, muscle moment arm and musculotendon length (origin to insertion length) can be computed. However, to find abductor torque (the product of muscle force and moment arm), muscle force must also be calculated.

To compute maximum isometric muscle force as a function of musculotendon length, a model was formulated for each of the five musculotendon compartments (one for the gluteus minimus, one for the tensor fasciae latae, and three for the gluteus medius). Each musculotendon model, which accounts for the static properties of both muscle¹⁶ and tendon³⁸ of that compartment, was formed from a generic model.³⁹ When the generic model is scaled by a muscle's physiologic cross-sectional area, optimal muscle fiber length, and tendon slack length, the force-length relation of a specific musculotendon compartment can be computed.³⁹ Nominal values for physiologic cross-sectional area were taken from Brand *et al.*⁶ Although data for muscle fiber lengths have been published for many muscles in the lower extremity,³⁷ none has been published for the hip abductors. However, J. A. Friederich and R. A. Brand have measured muscle fiber lengths for the hip abductors; their unpublished data were used in this study. When muscle attachments are specified, as above, tendon slack length (tendon's length at which force begins to develop on elongation of a musculotendon unit) determines the joint angles where a musculotendon compartment develops torque.³⁹ Tendon slack length was specified so that the abductor torque computed with the musculoskeletal model matched the torque measured during maximum voluntary

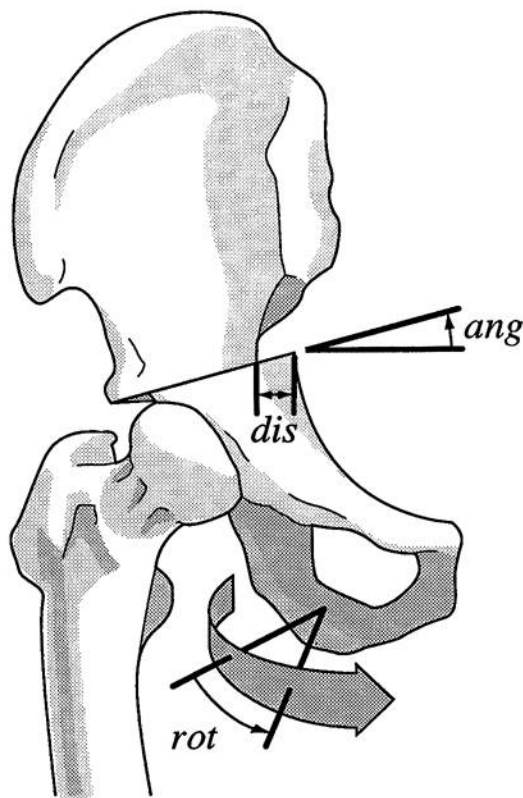


FIG. 1. Surgical parameters. The Chiari osteotomy was characterized by the angulation of the osteotomy (ang), distance of medial displacement (dis), and the internal rotation angle (rot).

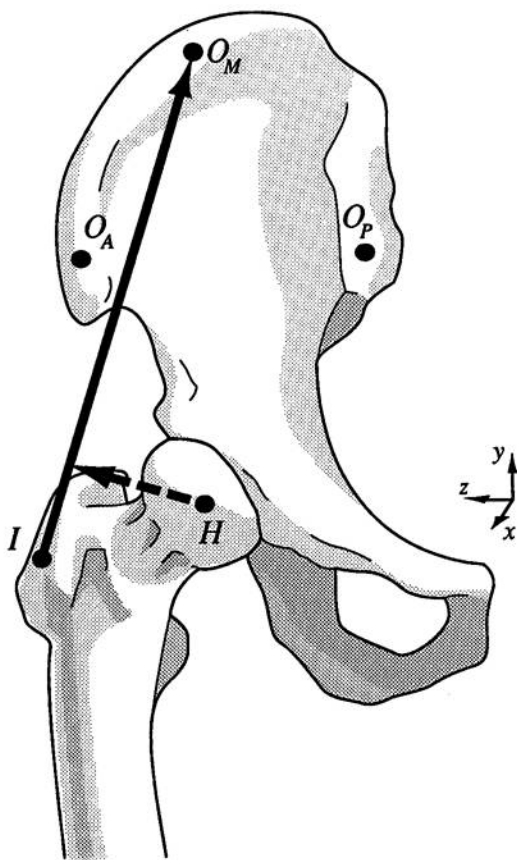


FIG. 2. Musculoskeletal coordinates for the gluteus medius. O_A , O_M , and O_P represent anterior, medial, and posterior muscle origins, respectively. I represents the muscle insertion. H is the hip joint center. The musculotendon length (solid line) and muscle moment arm (dashed line) can be computed from these coordinates.

contraction of the hip abductors under isometric conditions³¹ (Fig. 3). Passive muscle force was not included; hence, the musculotendon model computes maximum active muscle force (the force developed by a fully excited muscle after the passive force is subtracted) at any musculotendon length.

Once muscle attachment sites and musculotendon parameters were specified, maximum isometric hip abductor torque was computed as follows. First, at each joint angle, the length of each musculotendon compartment was calculated as the magnitude of the vector from its origin to its insertion. The musculotendon model was then used to find the muscle force at the computed length. Abductor torque for each muscle compartment

was computed as the moment of muscle force about the hip joint center. Individual muscle torques from the gluteus medius (three components), the gluteus minimus, and the tensor fasciae latae were summed to find the total abduction torque.

SIMULATIONS OF SURGERY

The surgical and musculoskeletal models were combined to simulate the effect of a Chiari osteotomy on abductor torque. To initiate a surgery simulation, a value for each surgical parameter was specified. The surgical model then computed the postsurgery muscle insertions and the joint center. These intermediate results were subsequently used in the musculoskeletal model to

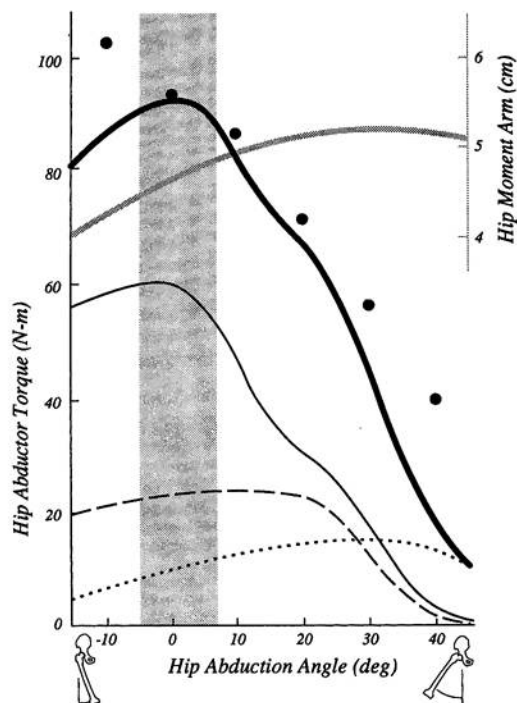


FIG. 3. Comparison of computed and experimental hip abductor torques. Computed torques of the tensor fasciae latae (dotted line), the gluteus minimus (dashed line), and the three compartments of the gluteus medius (thin solid line) were summed to produce the total computed torque (thick solid line), which compares well with abductor torque measurements³¹ (large dots). The average gluteus medius moment arm is the gray line. The vertical shaded area represents the range of hip abduction used in walking (-5° to $+7^\circ$).

compute postsurgery gluteus medius abductor torque for joint angles ranging from -15° to 45° abduction. Both presurgery and postsurgery torques were then plotted against joint angle.

RESULTS

Figure 3 compares the computed presurgery hip abductor torque to torque measured during maximum voluntary isometric contraction of the hip abductor muscles.³¹ Notice the close correspondence between computed and measured hip abductor torque (compare the thick solid line and the large dots). The peak torque and the shape of the curve (decreasing torque with abduction) generated by the model also correspond with other measurements of hip abductor strength.^{27,30}

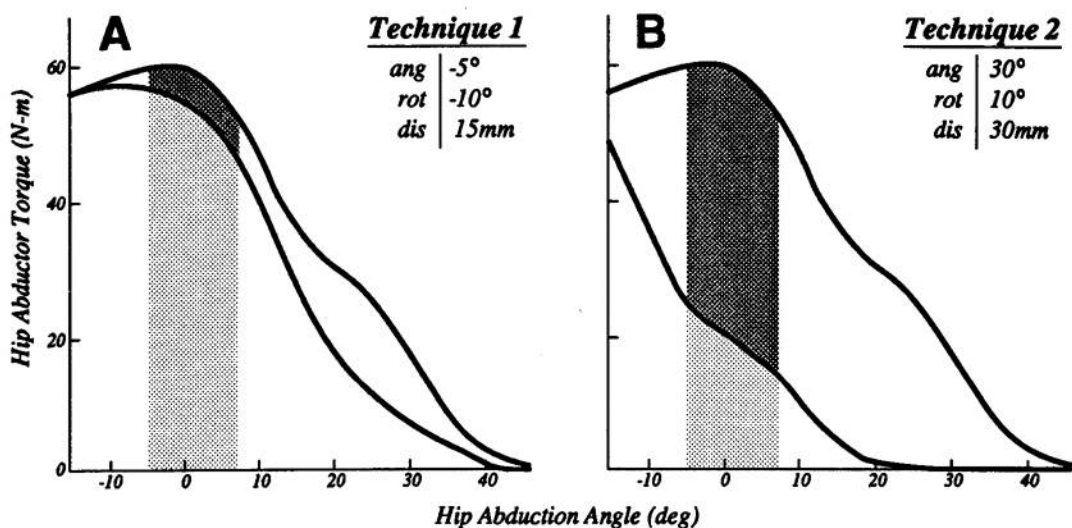
Torque decreases as the hip abducts because the muscles develop less force as their fibers shorten with abduction. The model shows that the gluteus medius moment arm does not decrease with abduction (gray line, Fig. 3). Moment arms of similar magnitude have also been measured roentgenographically.³¹ Since abductor torque is the product of muscle force and moment arm, and since moment arm does not decrease, the decrease in abductor torque with increasing abduction must result from decreased muscle force. It is also clear that abducting the hip brings the muscle origins and insertions closer together, thus shortening the muscle. As the muscle gets shorter with abduction, there is a decrease in muscle force. It can be concluded, therefore, that the hip abductors normally operate on the ascending region of their force-length curve.

Figure 3 also shows that the gluteus medius (thin solid line) contributes about 70% and the gluteus minimus (dashed line) contributes about 20% to the total hip abductor torque (thick solid line) near anatomic position (shaded region). Since these two muscles provide such a large proportion of the total torque, it is necessary that each muscle operates on the ascending region of its force-length curve (*i.e.*, force decreases as

the muscle shortens) in order to match experimental data.^{27,30,31} The gluteus medius and minimus have similar paths from the lateral surface of the ilium to the greater trochanter and were therefore affected similarly in the simulations of surgery. Because the gluteus medius is more than twice as strong as the gluteus minimus,^{6,12} and since the hip operates between -5° and 7° of abduction during gait,²⁴ the surgical simulation results focus on torque produced by the gluteus medius in that region.

Surgical simulation showed that some sets of surgical parameters conserve the gluteus medius abductor torque while others reduce it significantly. For example, with -5° angulation, 10° external rotation, and 15 mm medial displacement (Technique 1), postsurgery abductor torque is reduced by only 10% at anatomic position (Fig. 4A). In contrast, 30° angulation, 10° internal rotation, and 30 mm medial displacement (Technique 2) reduce postsurgery abductor torque by 65% at anatomic position (Fig. 4B).

Table 1 shows moment arm, muscle force, musculotendon length, change in musculotendon length, and abductor torque computed in the two simulated surgeries. With Technique 1, the average muscle moment arm is the same as before surgery; the musculotendon length is decreased by only 1 cm, and consequently the muscle force, which depends on muscle length,¹⁶ is reduced by only 15%. Since both moment arm and muscle force are altered very slightly, Technique 1 preserves abductor torque. Even though Technique 2 increases the muscle moment arm, there is a decrease in abductor torque because of reduced muscle force. The muscle is able to develop much less force because the high angulation, combined with the large medial displacement, brings the gluteus medius insertion closer to the origin, reducing the musculotendon length by 2.6 cm. Because the muscle fibers of the gluteus medius are short (5–8 cm), the 2.6-cm change represents a large decrease in length (52%–32%). This large decrease in muscle



FIGS. 4A AND 4B. Results of two surgery simulations. Presurgery gluteus medius abductor torque (upper curve) is compared with postsurgery gluteus medius torque (lower curve). The darkly shaded area highlights the difference between presurgery and postsurgery curves in the range of hip abduction used in walking (entire shaded area). (A) Technique 1, a nearly horizontal osteotomy, conserves abductor torque. (B) Technique 2, with high angulation, reduces abductor torque significantly.

fiber length causes a 68% reduction in muscle force in Technique 2.

Figures 5A–5D show how each surgical parameter affects the postsurgery abductor torque. Postsurgery abductor torque decreases as the angulation of the osteotomy increases (Fig. 5A), suggesting that angulation should be kept near the horizontal to preserve gluteus medius strength. The internal rotation angle has little effect on the postsurgery abductor torque (Fig. 5B). The effect of medial displacement depends on the

angulation. Figure 5C shows that increasing displacement significantly reduces abductor torque when angulation is above the horizontal. With a flat osteotomy (Fig. 5D), increasing the length of medial displacement has a small effect on abductor torque. A nearly horizontal osteotomy therefore allows large displacement without a significant decrease in abductor torque.

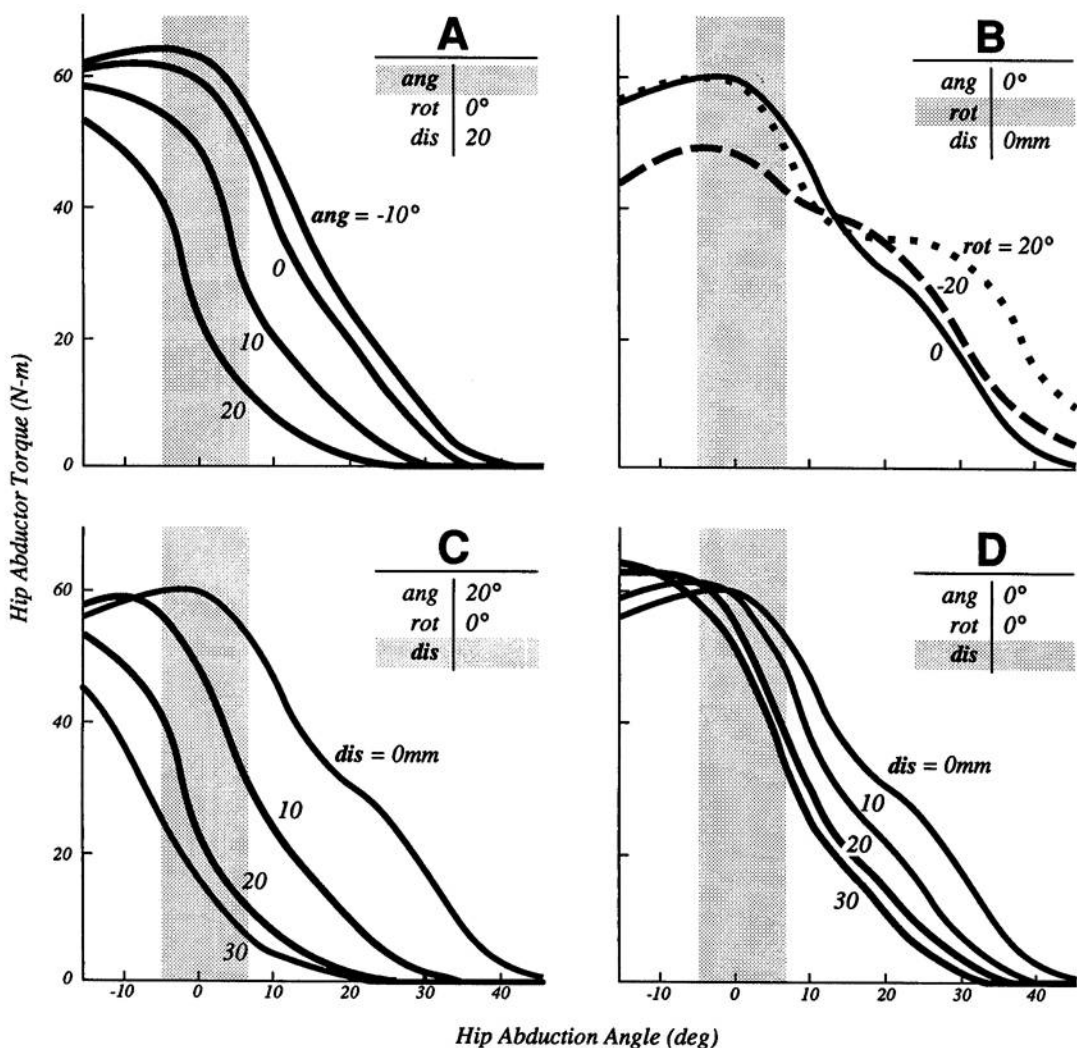
Hip abductor torque may decrease from a reduction in either muscle force or muscle moment arm. Because muscle force is a

TABLE 1. Gluteus Medius Parameters at Anatomic Position

Variable	Moment Arm (cm)*	Muscle Force (N)	Musculotendon Length (cm)*	Change in Musculotendon Length (cm)	Abductor Torque (Nm)**
Presurgery	4.5	1300	12.5	n/a	59
Technique 1 (Fig. 4A)	4.5	1100	11.5	-1.0	53
Technique 2 (Fig. 4B)	5.0	410	9.9	-2.6	21

* Average of the three gluteus medius components weighted by physiologic cross-sectional area.

** Abductor torque was computed as the sum of the individual torques from the three components of the gluteus medius, which does not necessarily equal average muscle moment arm times muscle force.



FIGS. 5A-5D. The effect of each surgical parameter on gluteus medius abductor torque. The shaded area represents the range of hip abduction used in walking. (A) Effect of angulation. Torque decreases as angulation increases, suggesting that the angulation should be kept as small as possible to preserve abductor torque. (B) Effect of internal rotation angle. Postsurgery gluteus medius abductor torque is higher with 20° internal rotation (dots) than with 20° of external rotation (dashes) because the maximum moment arm occurs at 15° internal rotation. The presurgery curve is the solid line. (C) Effect of medial displacement with large angulation. Abductor torque decreases as displacement increases when angulation is above the horizontal. (D) Effect of medial displacement with a flat osteotomy. Abductor torque is preserved, even with large displacement, when the osteotomy is horizontal.

function of its length,¹⁶ it is essential to consider the effect of surgery on musculotendon length. As the angle of the osteotomy is increased cephalad, the gluteus medius length is decreased. Also, when the angulation is above the horizontal plane, increasing the

length of medial displacement further reduces musculotendon length. Surgical simulations with both large angulation and displacement greatly reduce muscle length, leaving the muscle almost fully shortened at anatomic position. A reduction in muscle

length reduces muscle force, causing a large decrease in abductor torque. Internal rotation lengthens the posterior aspect of the gluteus medius and shortens the anterior aspect. External rotation has the opposite effect. In the model, the maximum frontal plane moment arm occurs at about 15° internal rotation. The reduction in abductor torque due to change in muscle moment arm was much less significant than the reduction caused by decreased muscle length.

DISCUSSION

The computer simulations of Chiari osteotomy mechanics show that certain sets of surgical parameters (*i.e.*, surgical techniques) cause a dramatic reduction (*e.g.*, 65%) in gluteus medius abduction torque. Is this enough to cause a limp? It has been estimated that the abductors must generate a force of approximately 1.5 times body weight for normal walking.²⁸ Under this assumption, a person weighing 78 kg must generate about 1200 N of abductor force to support the pelvis during gait. In a study of abductor muscle strength,³¹ 30 male subjects with an average weight of 78 kg produced an average abductor force of 2100 N at anatomic position. In this case, a 45% decrease in abductor strength would leave about 1200 N, the amount required for normal walking. Therefore, a decrease in force (torque) greater than 45% would presumably cause a limp. These experimental results agree with the clinical finding that near full strength of the hip abductors, unlike other muscle groups, is required for normal walking.³³

Because the changes in abductor torque due to moment arm effects are small compared to those caused by reduced muscle length, the limp from abductor weakness after the Chiari osteotomy is more likely caused by shortening the muscle than by reducing its moment arm. Bailey and Hall¹ suggested that shortening the gluteus medius caused the Trendelenburg gait. However, these authors explained the limp in terms of reduced muscle moment arm instead of reduced muscle force, stating that the Chiari

osteotomy "brings the insertion of the gluteus medius closer to its origin and destroys the fulcrum around which it functions, thus the often persistent Trendelenburg gait."¹ The computer model, which isolated the effects of muscle length and muscle moment arm, clearly showed that changing muscle length is more important than muscle moment arm.

Gougeon *et al.*¹⁸ suggested performing the Chiari osteotomy as vertically as possible (*i.e.*, with high angulation) to ease medial displacement and improve femoral head coverage. However, the computer simulations indicate that high angulation shortens the gluteus medius, causing a reduction in abductor torque, thus increasing the risk of a persistent limp. These results suggest that the angulation should be kept less than 10° above the horizontal to prevent excessive shortening of the gluteus medius and to preserve abductor strength. If a horizontal osteotomy is not possible, musculoskeletal geometry should still be adjusted to preserve the length of the gluteus medius.

Maintaining the length of the hip abductors is also important in other operative procedures. For example, trochanteric osteotomy has been proposed as a method for increasing the length of the hip abductor muscles to preserve abductor torque in patients being treated with total hip arthroplasty.⁸ While some have seen good results with this technique,^{8,15,25} others have reported little or no evidence of improved abductor strength with increasing length.^{17,29} A recent study of 53 patients, however, showed that the best torque values were achieved by keeping the gluteus medius within 1 cm of its original length.³ This clinical finding is in agreement with the model presented here, in which the gluteus medius operates near optimal length (producing maximum force) at anatomic position. In this case, both dramatic lengthening or shortening would result in decreased active muscle force at anatomic position. In Chiari's procedure, it is usually possible to maintain gluteus medius length without a trochanteric osteotomy.

It is important to discuss the assumptions and limitations of this type of study. First, with regard to the musculoskeletal model, it was assumed that the musculotendon parameters (physiologic cross-sectional area, optimal muscle fiber length, and tendon slack length) were not affected by the surgery. Only the effect of musculoskeletal geometry on abductor torque was considered, even though muscle atrophy or nerve damage could certainly cause abductor weakness. In fact, a wide variety of biologic and psychologic factors that could lead to the Trendelenburg limp were neglected because they are very difficult to model. For example, a post-operative patient apprehensive of pain may instinctively lean over the involved hip to decrease the compressive joint load by reducing the tension in the hip abductors. If this pattern of walking should become habitual, it could lead to disuse atrophy of the hip abductors and a chronic Trendelenburg limp. The causes of a limp after surgery are multifarious, and it was not the authors' intention to account for all of them. Rather, the objective was to determine whether there could be a biomechanical basis for the decrease in abductor strength after the Chiari osteotomy. For this purpose, analysis of a computer model that isolates the effects of each surgical parameter on abductor torque and leaves muscle physiologic properties constant, as performed here, seems to be a reasonable approach.

Second, the contribution of the gluteus maximus to abductor torque was not included. Although the anterior fibers of the gluteus maximus can contribute to abductor torque, modeling showed that they only become significant at high angles of abduction. Near the anatomic position (*i.e.*, near 0° of abduction), the gluteus maximus contributed very little to abductor torque. Because the hip operates near 0° abduction during walking,²⁴ this study focused on the gluteus medius since it provides such a large proportion of the total abduction torque in that region. Considering the gluteus medius alone is further justified by its similarity to the glu-

teus minimus since they were affected similarly in the surgery simulations and, together, contribute more than 80% of the total abductor torque near anatomic position.

Finally, the Chiari osteotomy was modeled with only three geometric parameters. Although the geometry of an osteotomy is certainly more complex (*e.g.*, there may be rotation about an anteroposterior axis), many clinically reasonable configurations of pelvic geometry may be approximated with these three parameters. The geometric changes calculated with the surgical model make intuitive sense (*e.g.*, high angulation combined with displacement shortens the gluteus medius) and are in accord with both the authors' anatomic study and geometric models of proximal femoral osteotomies.⁵

In summary, the conclusion that a nearly horizontal osteotomy preserves abductor torque is not sensitive to the details of the model, but is based only on the following general observations: (1) High angulation reduces the distance between origin and insertion of the gluteus medius. A more horizontal osteotomy preserves gluteus medius length. (2) Decreasing the length of the gluteus medius reduces the force it can develop, whereas maintaining its length preserves abductor muscle force and torque.

ACKNOWLEDGMENTS

The authors wish to thank David Delp for assistance in both computer programming and figure preparation, J. Peter Loan for help in computer programming, and Michael Roberts for help with the anatomic study. Melissa Hoy and Eric Topp have also been of great assistance in modeling the musculoskeletal system.

REFERENCES

1. Bailey, T. E., and Hall, J. E.: Chiari medial displacement osteotomy. *J. Pediatr. Orthop.* 5:635, 1985.
2. Betz, R. R., Kumar, S. J., Palmer, C. T., and MacEwen, G. D.: Chiari pelvic osteotomy in children and young adults. *J. Bone Joint Surg.* 70A:182, 1988.
3. Borja, F., Latta, L. L., Stinchfield, F. E., and Obreron, L.: Abductor muscle performance in total hip arthroplasty with and without trochanteric osteotomy. Radiographic and mechanical analyses. *Clin. Orthop.* 197:181, 1985.
4. Brand, R. A., Crowninshield, R. D., Wittstock,

- C. E., Pedersen, D. R., Clark, C. R., and van Krieken, F. M.: A model of lower extremity muscular anatomy. *J. Biomech. Eng.* 104:304, 1982.
5. Brand, R. A., and Pedersen, D. R.: Computer modeling of surgery and a consideration of the mechanical effects of proximal femoral osteotomies. *In* Welch, R. B. (ed.): *The Hip. Proceedings of the 12th Open Scientific Meeting of The Hip Society.* St. Louis, C. V. Mosby, 1984, pp. 193-210.
6. Brand, R. A., Pedersen, D. R., and Friederich, J. A.: The sensitivity of muscle force predictions to changes in physiologic cross-sectional area. *J. Biomech.* 19:8, 1986.
7. Calvert, P. T., August, A. C., Albert, J. S., Kemp, H. B., and Catterall, A.: The Chiari pelvic osteotomy: A review of the long-term results. *J. Bone Joint Surg.* 69B:551, 1987.
8. Charnley, J. C., and Ferreira, S. D.: Transplantation of the greater trochanter in arthroplasty of the hip. *J. Bone Joint Surg.* 46A:191, 1964.
9. Chiari, K.: Ergebnisse mit der Beckenosteotomie als Pfannendachplastik. *Z. Orthop.* 87:14, 1955.
10. Chiari, K.: Medial displacement osteotomy of the pelvis. *Clin. Orthop.* 98:55, 1974.
11. Chiari, K., and Schwager, X.: L'osteotomie pelvienne: Indications et resultats. *Rev. Chir. Orthop.* 62:560, 1976.
12. Clark, J. M., and Haynor, D. R.: Anatomy of the abductor muscles of the hip as studied by computed tomography. *J. Bone Joint Surg.* 69A:1021, 1988.
13. Colton, C. L.: Chiari osteotomy for acetabular dysplasia in young subjects. *J. Bone Joint Surg.* 54B:578, 1972.
14. DeWaal Malefut, M. C., Hoogland, T., and Neilsen, H. K. L.: Chiari osteotomy in the treatment of congenital dislocation and subluxation of the hip. *J. Bone Joint Surg.* 64A:996, 1982.
15. Eftekhar, N. S.: Surgical approaches to the hip. *In* Eftekhar, N. S. (ed.): *Principles of Total Hip Arthroplasty.* St. Louis, C. V. Mosby, 1978, pp. 35-37.
16. Gordon, A. M., Huxley, A. F., and Julian, F. J.: The variation in isometric tension with sarcomere length in vertebrate muscle fibers. *J. Physiol.* 184:170, 1966.
17. Gore, D. R., Murray, M. P., Gardner, G. M., and Sepic, S. B.: Roentgenographic measurements after Müller total hip replacement. *J. Bone Joint Surg.* 59A:948, 1977.
18. Gougeon, F., Duquennoy, A., and Fontaine, C.: L'osteotomie de Chiari: Difficultés de réalisation du contrat biomécanique. *Rev. Chir. Orthop.* 70:599, 1984.
19. Graham, S., Westin, G. W., Dawson, E., and Oppenheim, W. L.: The Chiari osteotomy: A review of 58 cases. *Clin. Orthop.* 208:249, 1986.
20. Hoffman, D. V., Simmons, E. H., and Barrington, T. W.: The results of the Chiari osteotomy. *Clin. Orthop.* 98:162, 1974.
21. Hogg, J., and MacNicol, M. F.: The Chiari pelvic osteotomy: A long-term review of clinical and radiographic results. *J. Bone Joint Surg.* 69B:365, 1987.
22. Inman, V. T.: Functional aspects of the abductor muscles of the hip. *J. Bone Joint Surg.* 29A:607, 1947.
23. Inman, V. T., Ralston, H. J., and Todd, F.: *Human Walking.* Baltimore, Williams & Wilkins, 1981, pp. 120-121.
24. Johnston, R. C.: Mechanical considerations of the hip joint. *Arch. Surg.* 107:411, 1973.
25. Lazansky, M. G.: Osteotomy of the greater trochanter: Part II. Trochanteric osteotomy of total hip replacement. *In* Harris, W. H. (ed.): *The Hip. Proceedings of the Second Open Scientific Meeting of The Hip Society.* St. Louis, C. V. Mosby, 1974, pp. 231-237.
26. MacNicol, M. F., Uprichard, H., and Mitchell, G. P.: Exercise testing after the Chiari pelvic osteotomy. *J. Bone Joint Surg.* 63B:321, 1981.
27. May, W. W.: Relative isometric force of the hip abductor and adductor muscles. *Phys. Ther.* 48:845, 1968.
28. McLeish, R. D., and Charnley, J. C.: Abduction forces in the one-legged stance. *J. Biomech.* 3:191, 1970.
29. Müller, M. E.: Osteotomy of the greater trochanter: Part I. Total hip replacement without trochanteric osteotomy. *In* Harris, W. H. (ed.): *The Hip. Proceedings of the Second Open Scientific Meeting of The Hip Society.* St. Louis, C. V. Mosby, 1974, pp. 231-237.
30. Murray, M. P., and Sepic, S. B.: Maximum isometric torque of hip abductor and adductor muscles. *Phys. Ther.* 48:1327, 1968.
31. Olson, M. A., Smidt, G. L., and Johnson, R. C.: The maximum torque generated by the eccentric, isometric, and concentric contractions of the hip abductor muscles. *Phys. Ther.* 52:149, 1972.
32. Pemberton, P. A.: Pericapsular osteotomy of the ilium for treatment of congenital subluxation and dislocation of the hips. *J. Bone Joint Surg.* 47A:65, 1965.
33. Perry, J.: Normal and pathologic gait. *In* AAOS Atlas of Orthotics. St. Louis, C. V. Mosby, 1985, pp. 76-111.
34. Salter, R. B.: Role of the innominate osteotomy in the treatment of congenital dislocation and subluxation of the hips in the older child. *J. Bone Joint Surg.* 48A:1413, 1966.
35. Salvati, E. A., and Wilson, P. D.: Treatment of irreducible hip subluxation by Chiari's iliac osteotomy: A report of results in 19 cases. *Clin. Orthop.* 98:151, 1974.
36. Schulze, H., and Kramer, J.: Ergebnisse der beken-osteotomie nach Chiari. *Z. Orthop.* 113:891, 1975.
37. Wickiewicz, T. L., Roy, R. R., Powell, P. L., and Edgerton, V. R.: Muscle architecture of the human lower limb. *Clin. Orthop.* 179:275, 1983.
38. Woo, S. L. Y., Gomez, M. A., Woo, Y. K., and Akeson, W. H.: Mechanical properties of tendons and ligaments: II. The relationship of immobilization and exercise on tissue remodeling. *Biorheology* 19:397, 1982.
39. Zajac, F. E.: Muscle and tendon: Properties, models, scaling, and application to biomechanics and motor control. *In* Bourne, J. (ed.): *CRC Critical Reviews in Biomedical Engineering*, vol. 17, issue 4. Boca Raton, Florida, CRC Press 1989, pp. 359-411.